


Modified Vestibular Incision Supraperiosteal Tunnel Access in Recession Type 2 with Thin Phenotype: A Report of Two Cases

SAKSHI MALHOTRA¹, SHIKHA TEWARI², RAJINDER KUMAR SHARMA³,
NISHI TANWAR⁴, RITIKA ARORA⁵



ABSTRACT

Gingival Recession Type 2 (RT2) presents complexity in achieving complete Root Coverage (RC) and associated parameters such as interproximal attachment loss and bone loss further have a negative influence on the stability of achieved RC. Complete RC might be attainable in RT2, though certain factors like tooth malposition, avascular root surface area, frenal pull, and thin Periodontal Phenotype (PP) may limit the amount of RC. Vestibular Incision Subperiosteal Tunnel Access (VISTA) technique proposed in the last decade has been promising in the maxillary anterior region in the management of Miller Class I/RT1 and even some RT2 gingival recession. In this case report, two systemically healthy female patients, having RT2 gingival recession in mandibular incisors labially positioned/rotated with thin PP were treated with Modified-vestibular incision supraperiosteal tunnel access (m-VISTA) along with Subepithelial Connective Tissue Graft (SCTG). Fifty percent RC was achieved in case-1 and 100% in case 2. The results were maintained during the follow-up period of nine months in case 1, and one year in case 2. Gingival RT2 with malpositioned tooth may be successfully treated with m-VISTA and SCTG as demonstrated in achieving stability of percentage RC and patients' satisfaction in terms of aesthetics and resolution of hypersensitivity in the present case report.

Keywords: Aesthetics, Connective tissue, Dentin hypersensitivity, Gingival recession, Regeneration

CASE REPORT

Case 1

A 27-year-old systemically healthy female patient reported with the chief complaint of mild hypersensitivity and aesthetic concern due to exposed root surface of lower front teeth for two years. On clinical examination isolated Miller class III or RT2 [1] was found in relation to rotated labially positioned mandibular left central incisor [Table/Fig-1a,b].

Clinical parameters included Probing Pocket Depth (PPD) [2], Clinical Attachment Loss (CAL) [2], Recession Depth (RD) [2], Recession Width (RW) [2], percentage Root Coverage (RC%=RD (preoperative-postoperative)/RD (preoperative)×100) [3], Gingival Thickness (GT) measured using a digital vernier calliper [4], PP based on periodontal probe translucency [5], Root Aesthetic Score (RES) [6], and patient- based evaluation of hypersensitivity and aesthetics using visual analogue scale (details of clinical findings are summarised in [Table/Fig-2,3]). A periodontal probe (PCP-UNC 15, Hu-Friedy, Chicago, USA) was used to measure periodontal parameters. Radiographic examination revealed interdental alveolar bone loss [Table/Fig-1c]. Level of alveolar bone crest from cemento-enamel junction was calculated by using Image-J software [7].

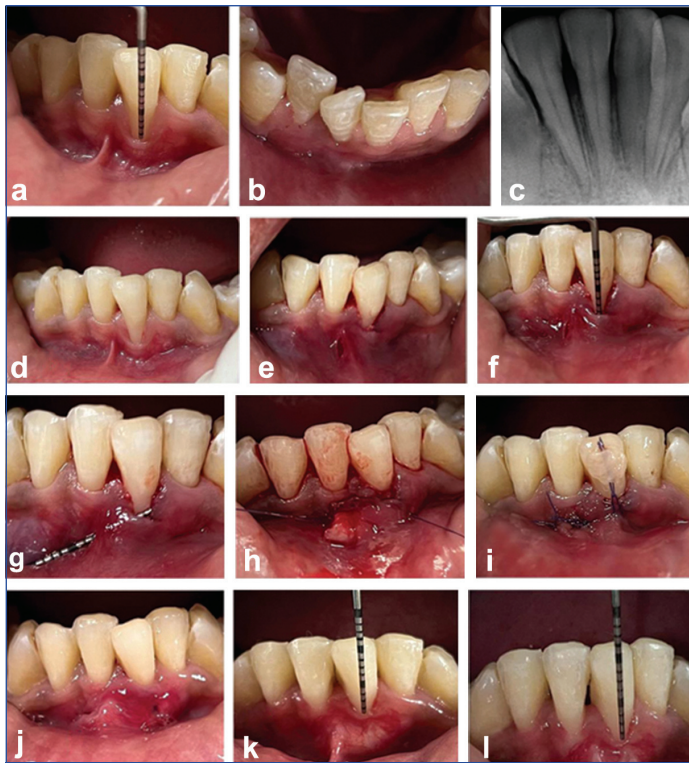
Thorough scaling and root planing were performed and modified (m) VISTA technique using SCTG was planned after obtaining written and informed consent. Root prominence was reduced with the burs (Mani Dia Burs, India)/curettes (Hu Friedy, Chicago, USA) [Table/Fig-1d]. After achieving local anaesthesia, a vertical incision was made with #15 blade (Surgeon blades and medical devices private limited, Gujrat, India), slightly distal to frenal area and beyond the mucogingival junction, through the periosteum to elevate a supraperiosteal tunnel using tunnelling instruments (GDC, India) [Table/Fig-1e]. The tunnel was extended mesially and distally of the tooth to be treated [Table/Fig-1g]. An intrasulcular incision was performed using surgical blade (#15 C, Hu-friedy, Chicago, USA) to detach the papillae and to mobilise gingival

margin [Table/Fig-1f]. The SCTG of adequate thickness and approximately three times the width of the recession defect was harvested from the palate through single incision technique [8], and inserted inside the prepared tunnel [Table/Fig-1h]. Graft and mucogingival-papillary complex were then advanced coronally and stabilised with a coronally anchored suture (5-0 Vicryl, Ethicon, Johnson & Johnson private limited, India) using composite resin (Charisma, Kulzer Mitsui chemicals group, Germany). The access vertical incision was also sutured using interrupted sutures [Table/Fig-1i].

Postoperative instructions were given and amoxicillin (Almox, Alkem laboratories Ltd., India) 500 mg 3/day×5 days, ibuprofen (Brufen, Abbott, India), 400 mg 3/day×3 days and 0.2% chlorhexidine (0.2% Hexidine, ICPA Health Product Ltd., India) mouthwash twice daily×14 days were prescribed. Patient was advised not to use mechanical means of plaque control until suture removal. The sutures were removed after 12-14 days [Table/Fig-1j]. Postoperative healing was uneventful and no complications were observed. After three months of surgery, 50% of RC was achieved [Table/Fig-1k] and remained stable till nine months of follow-up [Table/Fig-1l].

Case 2

An 18-year-old female patient reported with the chief complaint of mild hypersensitivity and aesthetic concern due to exposed root surface in relation to lower front teeth since one year. On clinical examination, isolated RT2 recession was found in relation to rotated labially positioned mandibular left central incisor [Table/Fig-4a]. Clinical parameters included were same as described above in case 1 [Table/Fig-2,3]. Radiographic examination revealed interdental alveolar bone loss in relation to mandibular left central incisor [Table/Fig-3,4b]. Thorough scaling and root planing was performed and surgery for recession coverage was planned after obtaining written and informed consent. The m-VISTA technique was used along with SCTG which was harvested from palate using single incision technique [Table/Fig-4c-f]. Postoperative instructions were given, same as described above in case 1. The sutures were



[Table/Fig-1]: Case 1 a) Preoperative image showing gingival recession in relation to labially positioned, rotated mandibular left central incisor; b) Incisal view showing labially positioned mandibular left central incisor; c) Preoperative radiograph showing interdental bone loss in relation to 31; d) Intraoperative image showing merged mesial line angle; e) Vertical incision given slightly distal to frenum; f) Probe showing intrasulcular tunnel; g) Supraperiosteal tunnel prepared; h) SCTG insertion into supraperiosteal tunnel; i) Coronally anchored suture secured with composite resin; j) Suture removal; k) Three months postoperative image showing partial Root Coverage (RC); l) Stability of achieved level of marginal gingiva at nine months of follow-up.

Case number	Tooth location and tooth number	Vestibular depth	Frenal pull	Number of surfaces involved	Tooth malposition	Interdental bone loss/attachment loss	Recession type
Case 1	Mandibular anterior, 31	Adequate	High frenal attachment	2 (labial and mesial surface)	Rotated labially positioned	Present	Miller Class III/RT2
Case 2	Mandibular anterior, 31	Adequate	High frenal attachment	1 (labial surface)	Slight rotation, labially positioned	Present	Miller Class III/RT2

[Table/Fig-2]: Preoperative clinical characteristics of teeth with gingival recession.

Clinical parameters	Case 1 (27/F)			Case 2 (18/F)		
	Preop.	3 months	9 months	Preop	6 months	1 year
Probing pocket depth	2	1	1	2	2	2
CAL [†] (M, MB, D) [‡]	3,6,2	2,3,2	2,3,1	3,4,3	2,2,2	1,2,1
Recession depth	4	2	2	2	0	0
Recession width	3	3	3	3	0	0
Keratinised tissue width	1	1	1	1	1	1
Periodontal phenotype	thin	thin	thin	thin	thin	thin
Gingival thickness	0.54	0.86	0.86	0.42	0.76	0.76
Mesial alveolar bone loss	3.89	-	-	2.86	-	-
Distal alveolar bone loss	3.12	-	-	2.64	-	-
Hypersensitivity (VAS)	3	0	0	2	0	0
Root coverage %	-	50	50	-	100	100
Root esthetic score	-	7	7	-	9	9
Patient satisfaction in terms of esthetics (VAS) ^{§§§}	-	8	8	-	10	10

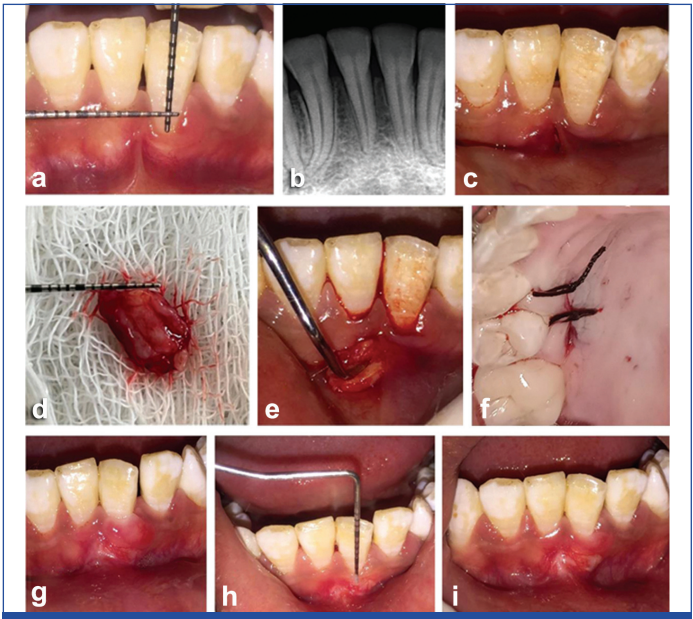
[Table/Fig-3]: Clinical parameters and patient related factors at baseline and follow-up in cases of RT2 gingival recession.
[†]Clinical attachment loss, [‡]Mesial, mid buccal, distal, ^{§§§}Visual analog scale

removed after 12-14 days [Table/Fig-4f,g]. Complete RC was achieved at six months of follow-up [Table/Fig-4h] and remained stable till one year of follow-up [Table/Fig-4i].

DISCUSSION

Intricacy in achieving complete RC in RT2 gingival recession may be due to certain crucial factors like interproximal soft tissue integrity, avascular root surface areas, and the dimension of the gingival recession along with interproximal attachment loss/bone loss [1,9]. VISTA technique proposed in the last decade has been promising in the maxillary anterior region in the management of Miller class 1/RT1 and even some RT2 gingival recession [Table/Fig-5] [10-15].

Zadeh HH et al., introduced VISTA approach, revealing several advantages of this minimally invasive approach by preparing a tunnel beyond the mucogingival junction with a single incision within the frenum which in turn [10], facilitates the low-tension coronal positioning of the gingival margins, maintaining the anatomical integrity of the interdental papillae and improves the aesthetic outcome. Modifications of this technique by Fernandez-Jimenez A et al., in treating multiple Miller class III recession included placement of composite bridges in the interproximal sites for suturing before the preparation of the surgical bed, vertical incision to the periosteum at the centre of the extension of treated teeth extending slightly beyond the mucogingival junction, intrasulcular incisions which extend to the papillae, and performing multiple vertical double-crossed sutures on the interdental composite sutures [15]. Chowdhary PC et al., reported a different modification in cases of Miller class I/II gingival recession by performing V-shaped incision in the frenal area for conducting both the m-VISTA and frenectomy techniques simultaneously and inserting



[Table/Fig-4]: Case 2 a) Preoperative image showing gingival recession in relation to rotated mandibular left central incisor; b) Preoperative radiograph showing interdental bone loss in 31; c) Vertical incision given slightly distal to frenum; d) Subepithelial Connective Tissue Graft (SCTG) harvested from palate; e) Intraoperative image showing insertion of SCTG in supraperiosteal tunnel; f) Suturing of single incision, given in palate to harvest SCTG; g) Suture removal; h) Complete Root Coverage (RC) at six months of follow-up; i) Stability of complete Root Coverage (RC) at one year of follow-up.

Author (year)	Type of study, place of study, (Patient number)	Arch and tooth type and number of teeth	Follow-up	Technique	Percentage root coverage (RC%)	Patient related factors
Zadeh HH [10] (2011)	Case report California, USA (N=2)	Maxillary arch, • Case 1: Miller Class II-11,21 • Case 2: Class I and II- all maxillary anterior teeth (n=8)	Case 1- 35 months Case 2- 20 months	VISTA with Rh PDGFBB*+BTCP†	100% root coverage	nil
Garg S et al., [11] (2017)	Case series, Greater Noida, India (N=4)	Maxillary arch Class I, III multiple recessions: Incisors, canines, premolars (n=16)	6 months	VISTA with PRF‡ and without PRF	Cases I and II of Class I-100% coverage Case III-100% RC with 80%-85% of CAL gain at site treated with VISTA+PRF-membrane Case IV-70% RC- with VISTA+PRF-membrane rather than 50% RC with VISTA technique.	nil
Gil A et al., [12] (2018)	Retrospective study utilising digital analysis California, USA (21)	Maxillary arch (n=73) Class I, II Multiple recessions: Incisor, canine, premolars and molars, and mandibular arch Cases (n=81), class III multiple recessions: Incisor, canine, premolars and molars, (n=154)	12 months	VISTA with Graft material (CT, ADMA§, XCM¶ in combination with PDGF)	Percentage of linear root coverage: ClassI/II-96.2±13.1% ClassIII-84.3±14.4% Complete root coverage ClassI/II-70.0% Class III-22.2%	nil
Spate US and Lee CT [13] (2019)	Case series, Texas, USA (3)	• Case 1: Miller Class I, 33,34,35,36 (mandible) • Case2: Miller class I (maxilla) 22,23 • Case 3: Miller class I (mandible) 44,45 (n=8)	12 months	VISTA-X Volume-stable collagen matrix (VCMX)	Cumulative coverage was 96.88% and 7 out of 8 sites showed complete root coverage	Resolution of hypersensitivity and improved esthetics, high patient satisfaction rate
Chowdary PC et al., [14] (2020)	Case report, Visakhapatnam, India (n=1)	Maxillary arch, multiple recession Class I, II: 11,12,13 (n=3)	9 months	m-VISTA**+CTG††, frenectomy and Supraperiosteal tunnel	Complete root coverage 100%	RES by both clinician and patient, Hypersensitivity
Fernández-Jiménez A et al., [15] (2021)	Case series, Basque Country, Spain (N=10)	• Mandibular arch cases (n=8)- Multiple class III: Incisors, canines, premolars and molars • Maxillary arch cases (n=2)- Multiple class III: Incisors, canines, premolars (n=38)	6 months	m-VISTA†† and CT	Mean RC %- 58.72±25.95% was achieved Complete RC was seen in 29% of the recessions and in 50% of the patients	VAS†† (pain and aesthetic)

[Table/Fig-5]: Evidence related to VISTA technique and its modifications used for Root Coverage (RC) in cases with gingival recession [10-15].

*Recombinant human platelet-derived growth factor BB, †Beta tri -calcium phosphate, ‡Platelet rich fibrin, §Acellular dermal matrix allograft, ¶Xenogenic collagen matrix, **m-VISTA: modified vestibular incision subperiosteal tunnel access, ††Connective tissue graft, †††Visual analog scale

SCTG in the supraperiosteal tunnel [14]. Gil A et al., conducted a retrospective study and reported percentage mean linear recession coverage of 84.3±14.4% in Miller class III in relation to different tooth type, performing VISTA using SCTG which was harvested from different sites and with use of other graft materials [12]. In a case series, Spate US and Lee CT utilised VISTA technique with volume stable collagen matrix for recession coverage in two premolars having gingival recession Miller class III. Volume stable collagen matrix is easy to perform with single operating site however, it is not cost-effective [13].

In the present case report, m-VISTA approach with SCTG was used to treat isolated RT2 gingival recession in mandibular anterior tooth, with an implementation of a vertical incision distant from the gingival margin, distal to the frenum to avoid tissue tear during the preparation of supraperiosteal tunnel in thin PP. After that, an intrasulcular incision was performed to disengage interdental papillae, which enables coronal repositioning of the whole papillary-mucogingival unit, and a coronally anchored suture using composite resin was given to stabilise the graft and mucogingival- papillary complex. Underlying frenal fibres were completely relieved. Root prominence was also reduced for the proper adaptation of SCTG without creating a dead space between the grafts and underlying root surfaces. SCTG may be considered as gold standard for gingival recession coverage and at the recipient site, it provides good colour match and aesthetics.

CONCLUSION(S)

The results showed the possibility of achieving stable RC and optimal aesthetics with m-VISTA technique along with SCTG performed to treat isolated RT2 gingival recession in malaligned mandibular anterior with thin PP.

REFERENCES

- [1] Cairo F, Nieri M, Cincinelli S, Mervelt J, Pagliaro U. The interproximal clinical attachment level to classify gingival recessions and predict root coverage outcomes: An explorative and reliability study. *J Clin Periodontol.* 2011;38(7):661-66.
- [2] Carranza FA, Newman MG. *Clinical Periodontology 8th Edition.* W. B Saunders Company. Philadelphia. 1996.
- [3] Shieh AT, Wang HL, O'Neal R, Glickman GN, MacNeil RL. Development and clinical evaluation of a root coverage procedure using a collagen barrier membrane. *J Periodontol.* 1997;68(8):770-78.
- [4] Sharma S, Thakur SL, Joshi SK, Kulkarni SS. Measurement of gingival thickness using digital vernier caliper and ultrasonographic method: A comparative study. *Journal of Investigative and Clinical Dentistry.* 2014;5(2):138-43.
- [5] Abraham S, Athira PR. Correlation of gingival tissue biotypes with age, gender and tooth morphology: A cross sectional study using probe transparency method. *IOSR J Dent Med Sci.* 2015;14:64-69.
- [6] Cairo F, Rotundo R, Miller Jr PD, Pini Prato GP. Root coverage esthetic score: A system to evaluate the esthetic outcome of the treatment of gingival recession through evaluation of clinical cases. *J Periodontol.* 2009;80(4):705-10.
- [7] Schneider CA, Rasband WS, Eliceiri KW. NIH Image to Image J: 25 years of image analysis. *Nature Methods.* 2012;9(7):671-75.
- [8] Hürzeler MB, Weng D. A single-incision technique to harvest subepithelial connective tissue grafts from the palate. *Int J Periodontics Restorative Dent* 1999;19(3):279-87.
- [9] Özcelik O, Seydaoglu G, Haytac MC. An explorative study to develop a predictive model based on avascular exposed root surface area for root coverage after a laterally positioned flap. *J Periodontol.* 2015;86(3):356-66.

- [10] Zadeh HH. Minimally invasive treatment of maxillary anterior gingival recession defects by vestibular incision subperiosteal tunnel access and platelet-derived growth factor BB. *Int J Periodontics Restorative Dent*. 2011;31(6):653-60.
- [11] Garg S, Arora SA, Chhina S, Singh P. Multiple gingival recession coverage treated with vestibular incision subperiosteal tunnel access approach with or without platelet-rich fibrin-A case series. *Contemp Clin Dent*. 2017;8(3):464-68.
- [12] Gil A, Bakhshalian N, Min S, Zadeh HH. Treatment of multiple recession defects with vestibular incision subperiosteal tunnel access (VISTA): A retrospective pilot study utilizing digital analysis. *J Esthet Restor Dent*. 2018;30(6):572-79.
- [13] Schulze-Späte U, Lee CT. Modified vestibular incision subperiosteal tunnel access procedure with volume-stable collagen matrix for root coverage: Report of three cases. *Int J Periodontics Restorative Dentistry*. 2019;39(5):e181-87.
- [14] Chowdary PC, Pavan Kumar YS, Murthy KR, Kishore DT. A novel modified-vista technique with connective tissue graft in the treatment of gingival recession-A case report. *Clin Adv Periodontics*. 2020.
- [15] Fernández-Jiménez A, Estefanía-Fresco R, García-De-La-Fuente AM, Marichalar-Mendia X, Aguirre-Zorzano LA. Description of the modified vestibular incision subperiosteal tunnel access (m-VISTA) technique in the treatment of multiple Miller class III gingival recessions: A case series. *BMC Oral Health*. 2021;21(1):142.

PARTICULARS OF CONTRIBUTORS:

1. Ex Postgraduate Student, Department of Periodontics, Post Graduate Institute of Dental Sciences, Rohtak, Haryana, India.
2. Senior Professor, Department of Periodontics, Post Graduate Institute of Dental Sciences, Rohtak, Haryana, India.
3. Senior Professor and Head, Department of Periodontics, Post Graduate Institute of Dental Sciences, Rohtak, Haryana, India.
4. Professor, Department of Periodontics, Post Graduate Institute of Dental Sciences, Rohtak, Haryana, India.
5. Associate Professor, Department of Periodontics, Post Graduate Institute of Dental Sciences, Rohtak, Haryana, India.

NAME, ADDRESS, E-MAIL ID OF THE CORRESPONDING AUTHOR:

Sakshi Malhotra,
Ex Postgraduate Student, Department of Periodontics, Post Graduate Institute of
Dental Sciences, Rohtak, Haryana, India.
E-mail: sakshi1828@gmail.com

PLAGIARISM CHECKING METHODS: [Jain H et al.]

- Plagiarism X-checker: Mar 31, 2023
- Manual Googling: Apr 06, 2023
- iThenticate Software: Apr 24, 2023 (13%)

ETYMOLOGY: Author Origin**AUTHOR DECLARATION:**

- Financial or Other Competing Interests: None
- Was informed consent obtained from the subjects involved in the study? Yes
- For any images presented appropriate consent has been obtained from the subjects. Yes

Date of Submission: **Mar 29, 2023**Date of Peer Review: **Apr 21, 2023**Date of Acceptance: **Apr 26, 2023**Date of Publishing: **May 01, 2023**